0363-5465/103/3131-0648$02.00/0
THE AMERICAN JOURNAL OF SPORTS MEDICINE, Vol. 31, No. 5
© 2003 American Orthopaedic Society for Sports Medicine

Reconstruction of the Coracoclavicular Ligaments with Tendon Grafts

A Comparative Biomechanical Study

Steven J. Lee,*† MD, Stephen J. Nicholas,* MD, Kenneth H. Akizuki,* MD, Malachy P. McHugh,* PhD, Ian J. Kremenic,* MEng, and Simon Ben-Avi,‡ PhD

*From the *Nicholas Institute of Sports Medicine and Athletic Trauma, Department of Orthopaedic Surgery, Lenox Hill Hospital, and ‡The Cooper Union for the Advancement of Science and Art, New York, New York*

Background: Numerous surgical techniques have been described to address injuries to the coracoclavicular ligaments.
Purpose: To compare the biomechanical properties of tendon graft reconstructions with those of the native coracoclavicular ligaments and various other repair methods.
Study Design: Controlled laboratory study.
Methods: Eleven fresh-frozen human cadaveric shoulders were tensile tested to failure to compare the biomechanical properties of the native coracoclavicular ligaments, coracoacromial ligament transfer, No. 5 Mersilene suture repair, 5-mm Mersilene tape repair, and tendon graft reconstructions with gracilis, semitendinosus, and long toe extensor tendons.
Results: Reconstructions with semitendinosus, gracilis, or long toe extensor tendon grafts were found to have superior initial biomechanical properties compared with coracoacromial ligament transfer; failure strengths were as strong as those of the native coracoclavicular ligaments. Failure of the tendon grafts occurred through the midsubstance of the tendon graft, not at the fixation site.
Conclusions: Tendon graft reconstruction may be an alternative to coracoacromial ligament transfer and may provide a permanent biologic reconstruction with superior initial biomechanical properties, including that of tensile strength.
Clinical Relevance: Use of tendon graft reconstruction may limit the need for postoperative immobilization and lead to an accelerated rehabilitation program.
© 2003 American Orthopaedic Society for Sports Medicine

Shoulder separations (acromioclavicular joint dislocations) and certain distal clavicle fractures (Neer type II A and B) are common injuries. Although controversy certainly exists concerning the optimal treatment of these injuries, whether surgical or not, there is even more controversy over the proper technique once operative treatment has been deemed necessary.[2,3,13,17,23,27,28,32,35,36,42,45] Numerous techniques have been described to address these injuries, yet, to date, no treatment has emerged as the ideal.[1,4–12,14,15,18–20,22,24–26,31,33,34,37,39–41,43,44,46,47,49]

The key anatomic structures affected by both shoulder separations and type II distal clavicle fractures are the coracoclavicular ligaments. The current operative methods of treatment focus on either primary healing of the coracoclavicular ligaments or on reconstruction of the ligaments with use of a local tissue source or a free tendon graft. The goal of primary healing of the coracoclavicular ligaments, by using various techniques such as sutures, tapes, suture anchors, and screws, is to hold the clavicle-coracoid relationship in a reduced position long enough to allow healing of the coracoclavicular ligaments. However, these techniques rely on the assumption that the coracoclavicular ligaments will heal not only at their normal preinjury length, but also at or near their prerupture tensile strength. If the coracoclavicular ligaments do not heal, the fixation methods may eventually fail, especially in those patients who place high demands on the shoulder.

Techniques for reconstruction of the coracoclavicular ligaments have also been developed. Transfer of the coracoacromial ligament to the distal end of the clavicle was

† Address correspondence and reprint requests to Steven J. Lee, MD, 130 East 77th Street, Black Hall, 5th Floor, New York, NY 10021.
No author or related institution has received any financial benefit from research in this study.

Downloaded from http://ajs.sagepub.com by MALACHY MCHUGH on November 12, 2008

well described by Weaver and Dunn.[46] Techniques that use a portion of the conjoined tendon and attach it to the clavicle through a drill hole or use a fascia lata tendon, palmaris longus tendon, or other free graft source to fix the clavicle to the coracoid have also been performed.[6,9,14,15,26,39,40,44,49] However, the weak initial fixation of the ligament or tendon to the clavicle can be a problem with use of these techniques.[21]

Common to all operative treatment techniques is a prolonged period of shoulder immobilization of up to 6 or 8 weeks and a return to sports not before 3 to 6 months after surgery.[30,37] Failure rates and incomplete reduction rates of up to 35% have been reported for the current operative treatments.[3,22,47]

The purpose of this study was to test, in a human cadaveric model, the biomechanical properties of a new reconstruction technique that uses various free tendon graft sources. These properties were compared with those of the normal intact coracoclavicular ligaments as well as traditional techniques such as the coracoacromial ligament transfer technique, suture, and suture tape repair. The ultimate goal of this study was to develop a better operative solution to this common injury, one that might have sufficient initial and ultimate strength to allow early motion, accelerated rehabilitation, earlier return to sports, and lower failure rates.

MATERIALS AND METHODS

Eleven fresh-frozen human whole cadaveric shoulders (seven male, four female) whose ages ranged from 44 to 65 years (average, 58) were thoroughly thawed and dissected. Only the coracoclavicular ligaments, coracoacromial ligament, the clavicle, and the scapula were preserved. The acromioclavicular ligament was sectioned. The clavicle was secured to a materials testing machine (MTS Systems Corp., Eden Prairie, Minnesota) with nuts and bolts through two drill holes into the clavicle that were connected with a 4.5-mm dynamic compression plate (Synthes, Paoli, Pennsylvania). The MTS clamp was secured onto the middle of the plate. The scapula was secured to the MTS by four 5.0-mm Schanz screws (Synthes), two into the scapular spine and two into the glenoid subchondral bone. A modified polymethyl methacrylate potting technique was used around the Schanz screws to ensure that no movement occurred at the screw-bone interface. The Schanz screws were connected via standard external fixation connecting bars (Synthes), and the MTS machine was secured onto the connecting bar (Fig. 1). This setup provided rigid fixation of the clavicle and scapula to the MTS machine and prevented all other displacements except for the direct superior displacement of the clavicle on the scapula.

Each of the 11 shoulder specimens underwent application of unidirectional load to failure of the normal intact coracoclavicular ligaments at a rate of 25 mm/min (Fig. 1). The following reconstructions were then performed: 1) 11 coracoacromial ligament transfers, 2) 11 suture repairs with use of No. 5 Mersilene suture (Ethicon Inc., Somerville, New Jersey), 3) 11 suture repairs with use of 5-mm Mersilene tape (Ethicon), and 4) reconstructions with three different tendon grafts (8 gracilis, 8 semitendinosus, and 10 long toe extensor tendons). The order of testing was not randomized and proceeded in the following order: native coracoclavicular ligaments, coracoacromial ligament transfer, one of three tendon graft reconstructions, suture repair, and then tape repair in the last two. Between each trial, the clavicle, scapula, and fixation materials were inspected. Unless a fracture or deformation occurred, the same scapula and clavicle was used for each of the subsequent reconstructions.

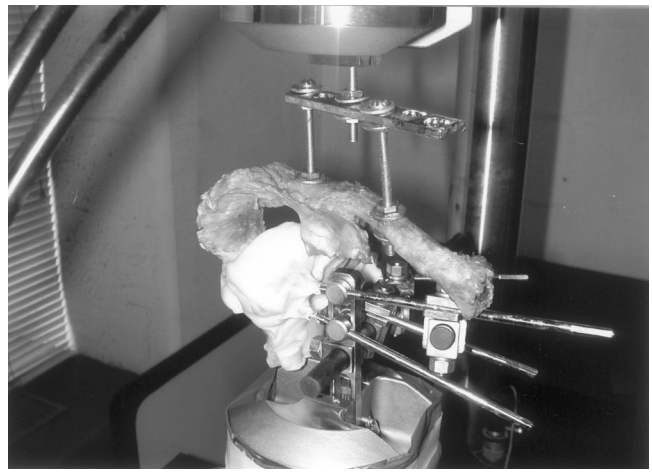

Figure 1. Shoulder specimen mounted to the materials testing system via specially designed clamps and a modified potting technique.

The coracoacromial ligament transfer was performed as described by Weaver and Dunn.[46] A 1-cm portion of the distal clavicle was excised first. The coracoacromial ligament was then released from its insertion under the acromion and transferred to the intramedullary canal of the clavicle. A Bunnell-type weave with a No. 1 Mersilene suture was placed into the coracoacromial ligament and was secured to the clavicle through two 1.6-mm drill holes into the superior cortex.

Suture reconstructions were performed with No. 5 Mersilene suture and 5-mm Mersilene tape (Fig. 2). The suture or tape was looped under the coracoid process, then threaded through a 4.0-mm drill hole in the anterior third of the clavicle and tied to itself. Load-displacement values were analyzed to failure on the MTS machine.

Reconstruction Technique

Tendon grafts were harvested from 10 separate fresh-frozen human cadaveric legs (six male, four female) whose ages ranged from 49 to 76 years (average, 62). The following tendon grafts were harvested from each leg: semitendinosus, gracilis, and long toe extensor. They were then used to reconstruct the coracoclavicular ligaments (Fig. 3).

A 4.0-mm drill hole was made in the anterior third of the clavicle at approximately the same level as the native coracoclavicular ligament insertion. The tendon graft was

Downloaded from http://ajs.sagepub.com by MALACHY MCHUGH on November 12, 2008

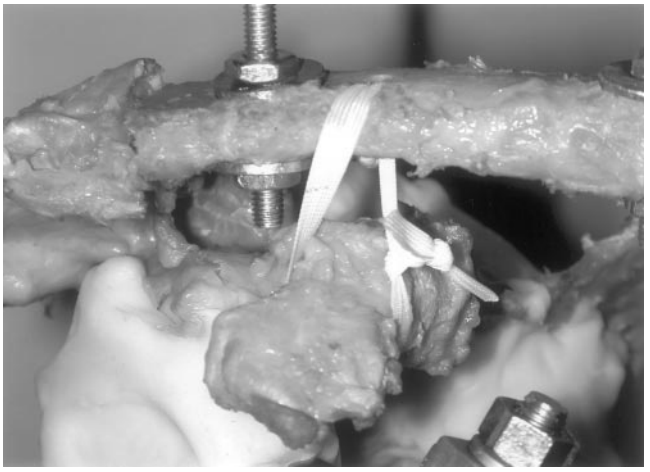

Figure 2. Five-mm Mersilene tape is looped under the coracoid and through a drill hole in the clavicle, then tied on the medial side.

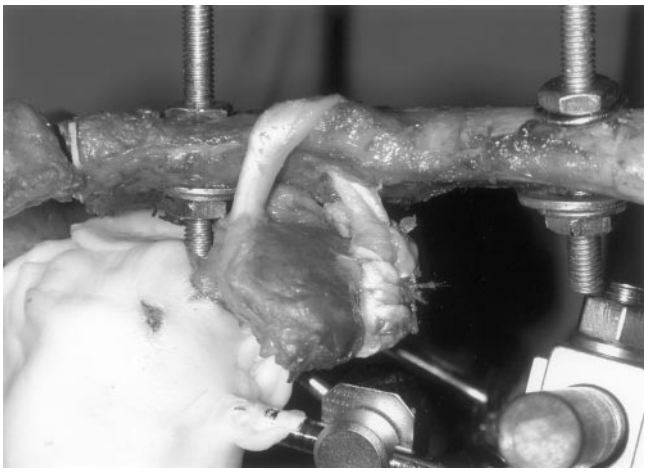

Figure 3. Reconstruction with a gracilis tendon graft. The tendon ends are tied in a knot on the medial side, and supplemental sutures help to secure the knot.

threaded through this hole and looped under the coracoid. The free ends of the graft were then secured on the medial side of the coracoid by tying the tendon ends into a double surgical knot and by using supplemental side-to-side sutures on the knot.

This fixation method was chosen for all the tendon graft reconstructions based on results from preliminary studies. Three different types of fixation methods were tested: suturing the tendon side-to-side, weaving the tendon with a Pulvertaft-type technique, and tying the tendon graft into a knot with supplemental sutures. Three toe extensor tendon grafts were used for each fixation method. The knot method had the highest load to failure and was the only method that predictably failed at the midsubstance of the tendon graft, not at the fixation site. Therefore, all tendon graft reconstructions were tested on the MTS machine by using the knot fixation method.

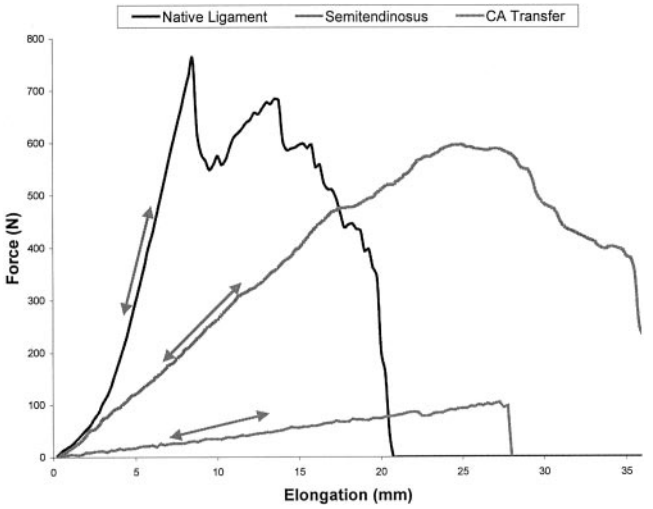

Figure 4. Load-elongation curves for the native coracoclavicular ligaments, a semitendinosus graft, and a coracoacromial transfer. The arrows indicate the portions of the curves that were used to calculate stiffness.

Testing

Load-displacement values were recorded continuously. For each specimen, peak load, load at 2-cm displacement (amount of distance approximating a grade 3 acromioclavicular separation and, thus, failure), linear stiffness, elongation at peak load, and the mode of failure were identified. If peak load occurred before 2 cm of elongation, only peak load was reported. One-way analysis of variance with Scheffé post hoc pairwise comparisons was used to test for differences in peak load, linear stiffness, and elongation at failure between the seven constructs tested (native ligament, coracoacromial transfer, tape, suture, gracilis tendon graft, toe extensor tendon graft, and semitendinosus tendon graft). The independent variable in the analysis of variance was a between-subjects factor (seven levels). A P value of 0.05 was used to denote level of significance.

RESULTS

Load at Failure

Typical load-elongation curves for the native ligaments, coracoacromial transfer, and semitendinosus tendon graft are shown in Figure 4. Peak load for the native ligaments was higher than for the coracoacromial ligament transfer ($P < 0.0001$), the suture repair ($P < 0.0001$), and the tape repair ($P = 0.05$), but was not different from the semitendinosus ($P = 0.99$), toe extensor ($P = 0.65$), or gracilis tendon reconstructions ($P = 0.78$). Similar results were seen for load at 2-cm elongation (Fig. 5). All tendon graft reconstructions were significantly stronger ($P < 0.05$) than the coracoacromial ligament transfer and suture repairs, but not significantly different from the Mersilene tape technique. Within the three tendon graft reconstruc-

Downloaded from http://ajs.sagepub.com by MALACHY MCHUGH on November 12, 2008

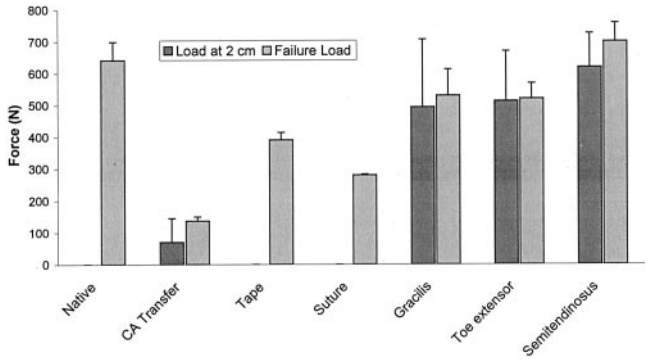

Figure 5. Ultimate failure load and load at 2-cm elongation (mean ± SD) for each test condition (all specimens failed before 2 cm for the native ligaments, tape repairs, and suture repairs). CA, coracoacromial.

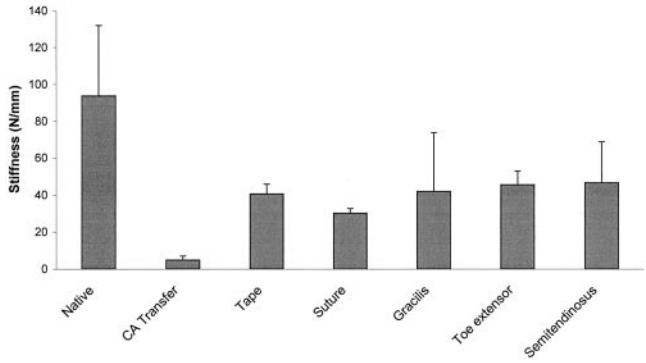

Figure 6. Linear stiffness (mean ± SD) for each test condition. CA, coracoacromial.

tions, no significant differences in strength were identified.

Stiffness

The native coracoclavicular ligaments were stiffer than all of the operative techniques ($P < 0.01$) (Fig. 6). Among the operative techniques, all three tendon graft reconstructions and the suture and tape repairs led to stiffer ligaments than did the coracoacromial ligament transfer (semitendinosus tendon, toe extensor tendon, tape, and suture, $P < 0.01$; gracilis tendon, $P < 0.05$). Stiffness after the suture and tape repairs was not different from that after the tendon graft reconstructions ($P = 0.5$ to 0.9). Among the three tendon graft reconstructions, no significant differences in stiffness were identified.

Elongation

Elongation at failure (Fig. 7) for the native coracoclavicular ligaments was significantly less than that for the coracoacromial ligament transfer ($P < 0.001$) and for reconstruction with the semitendinosus tendon ($P < 0.05$). There were no differences in elongation between the other techniques. All of the native ligaments, suture repairs, or

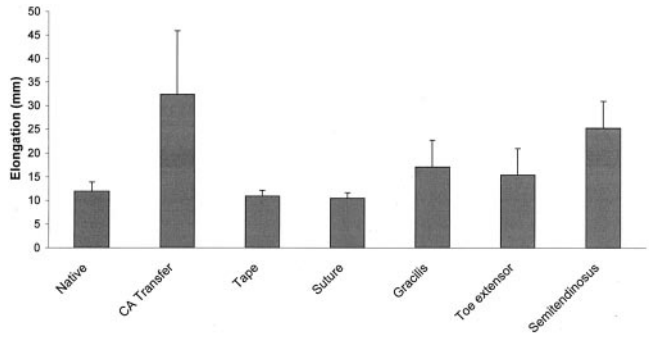

Figure 7. Elongation at failure (mean ± SD) for each test condition. CA, coracoacromial.

tape repairs failed before 2 cm of elongation. Two of 11 coracoacromial ligament transfers, 3 of 8 semitendinosus tendon grafts, 6 of 8 gracilis tendon grafts, and 9 of 10 toe extensor tendon grafts failed before 2 cm elongation.

Mode of Failure

The native coracoclavicular ligaments predictably failed at midsubstance. The coracoacromial ligament transfer technique failed through the suture next to the knot at the interface with the clavicle. All Mersilene suture and Mersilene tape repairs failed through the Mersilene itself next to the knot. All but two of the tendon graft reconstructions failed through the midsubstance of the tendon, not at the fixation site. The other two tendon graft reconstructions fractured at the base of the coracoid process at the highest loads of the eight reconstructions. No other discernible deformations occurred to the clavicle, scapula, or fixation sites.

DISCUSSION

The choice of the best operative technique for the treatment of acromioclavicular separations and type II distal clavicle fractures is certainly a controversial issue. What is not controversial, however, is the crucial role the coracoclavicular ligaments play in these injuries. Operative procedures that have been described include the use of K-wires, Steinmann or other types of pins, plates, wires, sutures, suture anchors, tapes, screws, tension banding, coracoacromial ligament transfers, conjoined tendon transfers, and tendon grafts.[1,4–12,14,15,18–20,22,24–26,31,33,34,37,39–41,43,44,46,47,49]

These various current operative treatments can be broadly classified into two groups: those that focus on the primary healing of the coracoclavicular ligaments and those meant to reconstruct the coracoclavicular ligaments. The first group attempts to hold the clavicle-coracoid relationship in a reduced position long enough to allow primary healing of the coracoclavicular ligaments. These techniques can be further subdivided into those methods that fix the acromioclavicular joint, such as with K-wires, Steinmann pins, or tension bands, and those that fix the coracoclavicular relationship with screws, sutures, suture

Downloaded from http://ajs.sagepub.com by MALACHY MCHUGH on November 12, 2008

anchors, tapes, and direct suture repair of the coracoclavicular ligaments. However, all of these techniques rely on the assumption that the coracoclavicular ligaments will heal not only at its normal preinjury length, but also at or near its prerupture tensile strength. If the coracoclavicular ligaments do not heal, all the previously mentioned fixation methods may eventually fail.

The second group of treatments focuses on the reconstruction of the coracoclavicular ligaments, in the form of transferring local tissue sources to the clavicle or by using free tendon grafts, either autografts or allografts. Transfer of the coracoacromial ligament and use of a portion of the conjoined tendon and attaching it to the clavicle have been well described.[12,39,46] Because this group of treatments does not affect the torn native coracoclavicular ligaments and yet also attempts to hold the clavicle-coracoid relationship in a reduced position, the ultimate strength of the tendon graft reconstruction and the primary healing of the torn native coracoclavicular ligaments may be additive. However, one common problem with these techniques remains the weak initial fixation of the ligament or tendon to the clavicle. Recent biomechanical tests have found the initial fixation strength of coracoacromial ligament transfers to be approximately one-fourth that of the normal coracoclavicular ligaments.[21] This finding has been confirmed in our study.

Transfer of the coracoacromial ligament to the distal end of the clavicle is a well-accepted treatment, especially for a chronic symptomatic acromioclavicular separation. However, the relatively weak strength of this reconstruction can lead to an incomplete reduction or recurrence, which has been reported to be as high as 24%.[46] Also, the importance of the coracoacromial ligament to proper shoulder function has been increasingly recognized. It is no longer thought that, because the coracoacromial ligament attaches two portions of the same bone, it does not have a significant function. Instead, its role in shoulder stability, not only to prevent superior migration of the humeral head, but also anterior and inferior instability, has been well documented.[16,29,38,48] Although this has not been reported to be a clinical problem in the absence of rotator cuff tears or hemiarthroplasty, transfer of this ligament to potentially take away its native function to perform another function should not be done indiscriminately.

In this study, we found that the knot fixation technique provided impressive fixation strength to the point that it was not the weakest link. By using this method, the tendon graft reconstructions were significantly stronger, stiffer, and elongated less than the coracoacromial ligament transfers. They were also significantly stronger than use of No. 5 Mersilene suture. In fact, the knot fixation technique compared favorably in strength to that of the native coracoclavicular ligaments, and none of the grafts were significantly different in failure strength from the native ligament.

Use of the No. 5 Mersilene sutures and 5-mm Mersilene tape also provided better initial fixation strength and stiffness and elongated less than did the coracoacromial ligament transfers. Compared with coracoacromial ligament reconstructions, however, these techniques do not provide a lasting biologic solution. Their role is merely to hold the clavicular-coracoid distance in a reduced position long enough to allow for healing of the native coracoclavicular ligaments. If the native coracoclavicular ligaments do not heal to their preinjury strength or length, the sutures or tapes may not withstand the cyclic loads and stresses placed upon the shoulder and may eventually fail. Performing a suture or tape reconstruction in combination with a coracoacromial ligament transfer, as is commonly done, may address these concerns.

The decision as to which of the tendon grafts to use is not clear. No significant differences were found for strength and stiffness among the three graft choices. The semitendinosus tendon graft did elongate longer than the toe extensor tendon graft, but this difference was not significant. Harvesting of the tendon grafts has been shown to have minimal morbidity; however, no studies have shown that any of these three tendon grafts have any significant advantages in terms of donor site morbidity. Other commonly used graft sources, such as the palmaris longus tendon, could be used, but were not tested in this study due to cadaver restraints. Therefore, if tendon grafts are to be used for the reconstruction of the coracoclavicular ligaments, the graft choice would best be left to surgeon's preference.

Reconstruction of the coracoclavicular ligaments with a tendon graft may offer many advantages with minimal morbidity. It is a biologic fixation that should be vascularized and incorporated as living tissue and can respond to the stresses and strains like any other graft, such as an ACL or ulnar collateral ligament reconstruction. Unlike these reconstructions, however, tendon graft reconstruction does not replace the torn native ligament but instead augments it. As such, the ultimate strength of the tendon reconstruction plus the primary healing of the torn native coracoclavicular ligaments may yield a higher strength than any of the currently used repairs that rely on the primary healing of the coracoclavicular ligaments alone and may yield a higher ultimate strength than even that of the native uninjured coracoclavicular ligaments. Further studies are required to substantiate these assertions, however.

Experimentally, it was found that a graft length of at least 16 cm was needed to securely fix the tendon graft with use of the knot technique. Tying the tendon graft into a double knot resulted in a fixation that was stronger than the graft itself, as evidenced by the fact that none of the tendon graft reconstructions failed at the fixation site. All failed through the tendon midsubstance or fractured the coracoid base. This finding eliminates a major limitation in the use of local tissue sources for reconstruction, namely the initial fixation strength.

Several important considerations are not addressed by this preliminary biomechanical study and will need to be studied in the future. First, while the initial biomechanical properties of tendon graft reconstructions appear to be promising, the effects of cyclic loading on coracoclavicular tendon graft reconstructions have not been studied. It may well be that cyclic loading may lead to progressive lengthening or even early failure of the tendon graft. Sec-

Downloaded from http://ajs.sagepub.com by MALACHY MCHUGH on November 12, 2008

ond, revascularization of the graft is assumed, but again, has not been studied. If the tendon graft does not become revascularized, it may not be able to respond to stresses and strains in a viscoelastic manner. Meanwhile, if revascularization does occur, it may lead to temporary weakening of the tendon graft compared with its initial fixation strength. Third, the viscoelastic properties of the various grafts may differ with respect to the native ligament, and this difference may have implications for graft failure at high loading rates similar to those that created the initial injury in vivo.

Furthermore, this study individually compared tendon graft reconstructions with various individual types of fixation methods. Weaver and Dunn[46] originally described transfer of the end of the coracoacromial ligament to the clavicle without supplemental fixation, and, therefore, this was what was tested in this study. Clinically, coracoacromial ligament transfers are currently often augmented with various other fixation methods, such as use of sutures or hardware to protect the repair. Similarly, tendon graft reconstructions may benefit from augmentation with absorbable sutures to protect the repair, limit the amount of possible stretching, and counteract the weakening effects of revascularization. Because of constraints from the use of cadavers, we were not able to directly compare these augmented combinations, and they must be extrapolated. Moreover, we studied unidirectional load displacement, whereas the actual coracoclavicular ligaments undergo stresses in multiple planes. Finally, clinical studies and long-term follow-up studies will be necessary to determine the true indications for tendon graft reconstruction of the coracoclavicular ligaments.

Nevertheless, tendon graft reconstructions show early promise. The most appropriate possible future indication for use of tendon grafts might be any time a coracoacromial ligament transfer has been indicated. Tendon graft reconstructions may offer significant benefits over the coracoacromial ligament transfer, namely, providing significantly increased initial failure strength and stiffness. Expansion of the indications to include acute acromioclavicular separations could be feasible because of the impressive initial fixation strength and the anticipated increased overall failure strength of the reconstruction and the healed native coracoclavicular ligaments. Ultimately, this may allow for a much more aggressive rehabilitation program, earlier return to sports and work, and better outcomes.

ACKNOWLEDGMENT

The authors acknowledge Eric Spencer, MD, for his help in the preparation of the manuscript.

REFERENCES

1. Ahstrom JP Jr: Surgical repair of complete acromioclavicular separation. *JAMA 217:* 785–789, 1971
2. Bakalim G, Wilppula E: Surgical or conservative treatment of total dislocation of the acromioclavicular joint. *Acta Chir Scand 141:* 43–47, 1975
3. Bannister GC, Wallace WA, Stableforth PG, et al: The management of acute acromioclavicular dislocation: A randomised prospective controlled trial. *J Bone Joint Surg 71B:* 848–850, 1989
4. Bargren JH, Erlanger S, Dick HM: Biomechanics and comparison of two operative methods of treatment of complete acromioclavicular separation. *Clin Orthop 130:* 267–272, 1978
5. Bearden JM, Hughston JC, Whatley GS: Acromioclavicular dislocation: Method of treatment. *J Sports Med 1:* 5–17, 1973
6. Berson BL, Gilbert MS, Green S: Acromioclavicular dislocations: Treatment by transfer of the conjoined tendon and distal end of the coracoid process to the clavicle. *Clin Orthop 135:* 157–164, 1978
7. Bosworth BM: Acromioclavicular separation: New method of repair. *Surg Gynecol Obstet 73:* 866–871, 1941
8. Bundens WD Jr, Cook JI: Repair of acromioclavicular separations by deltoid-trapezius imbrication. *Clin Orthop 20:* 109–114, 1961
9. Bunnell S: Fascial graft for dislocation of the acromioclavicular joint. *Surg Gynecol Obstet 46:* 563–564, 1928
10. Burri C, Neugebauer R: Carbon fiber replacement of the ligaments of the shoulder girdle and the treatment of lateral instability of the ankle joint. *Clin Orthop 196:* 112–117, 1985
11. Clayer M, Slavotinek J, Krishnan J: The results of coraco-clavicular slings for acromioclavicular dislocation. *Aust N Z J Surg 67:* 343–346, 1997
12. Copeland S, Kessel L: Disruption of the acromioclavicular joint: Surgical anatomy and biological reconstruction. *Injury 11:* 208–214, 1980
13. Cox JS: Current method of treatment of acromioclavicular joint dislocations. *Orthopedics 15:* 1041–1044, 1992
14. Dewar FP, Barrington TW: The treatment of chronic acomioclavicular dislocation. *J Bone Joint Surg 47B:* 32–35, 1965
15. Ferris BD, Bhamra M, Paton DF: Coracoid process transfer for acromioclavicular dislocations: A report of 20 cases. *Clin Orthop 242:* 184–194, 1989
16. Field LD, Dines DM, Zabinski SJ, et al: Hemiarthroplasty of the shoulder for rotator cuff arthropathy. *J Shoulder Elbow Surg 6:* 18–23, 1997
17. Galpin RD, Hawkins RJ, Grainger RW: A comparative analysis of operative versus nonoperative treatment of grade III acromioclavicular separations. *Clin Orthop 193:* 150–155, 1985
18. Graves SE, Foster BK: Absorbable suture lasso in the treatment of complete disruption of the acromioclavicular joint. *J Bone Joint Surg 66B:* 789–790, 1984
19. Gurd FB: The treatment of complete dislocation of the outer end of the clavicle: A hitherto undescribed operation. *Ann Surg 113:* 1094–1098, 1941
20. Habernek H, Weinstabl R, Schmid L, et al: A crook plate for treatment of acromioclavicular joint separation: Indication, technique, and results after one year. *J Trauma 35:* 893–901, 1993
21. Harris RI, Wallace AL, Harper GD, et al: Structural properties of the intact and the reconstructed coracoclavicular ligament complex. *Am J Sports Med 28:* 103–108, 2000
22. Hessmann M, Gotzen L, Gehling H: Acromioclavicular reconstruction augmented with polydioxanone sulphate bands. Surgical technique and results. *Am J Sports Med 23:* 552–556, 1995
23. Imatani RJ, Hanlon JJ, Cady GW: Acute complete acromioclavicular separation. *J Bone Joint Surg 57A:* 328–332, 1975
24. Inman VT, McLaughlin HD, Nevaiser J, et al: Treatment of complete acromioclavicular dislocation. *J Bone Joint Surg 44A:* 1008–1011, 1962
25. Kawabe N, Watanabe R, Sato M: Treatment of complete acromioclavicular separation by coracoacromial ligament transfer. *Clin Orthop 185:* 222–227, 1984
26. Laing PG: Transplantation of the long head of the biceps in complete acromioclavicular separations. *J Bone Joint Surg 51A:* 1677–1678, 1969
27. Larsen E, Bjerg-Nielsen A, Christensen P: Conservative or surgical treatment of acromioclavicular dislocation: A prospective, controlled randomized study. *J Bone Joint Surg 68A:* 552–555, 1986
28. Larsen E, Hede A: Treatment of acute acromioclavicular dislocation: Three different methods of treatment prospectively studied. *Acta Orthop Belg 53:* 480–484, 1987
29. Lee TQ, Black AD, Tibone JE, et al: Release of the coracoacromial ligament can lead to glenohumeral laxity: A biomechanical study. *J Shoulder Elbow Surg 10:* 68–72, 2001
30. Lemos MJ: The evaluation and treatment of the injured acromioclavicular joint in athletes. *Am J Sports Med 26:* 137–144, 1998
31. Lizaur A, Marco L, Cebrian R: Acute dislocation of the acromioclavicular joint. Traumatic anatomy and the importance of deltoid and trapezius. *J Bone Joint Surg 76B:* 602–606, 1994
32. MacDonald PB, Alexander MJ, Frejuk J, et al: Comprehensive functional analysis of shoulders following complete acromioclavicular separation. *Am J Sports Med 16:* 475–480, 1988
33. Morrison DS, Lemos MJ: Acromioclavicular separation: Reconstruction using synthetic loop augmentation. *Am J Sports Med 23:* 105–110, 1995
34. Mumford EB: Acromioclavicular dislocation. *J Bone Joint Surg 23:* 799–802, 1941
35. Park JP, Arnold JA, Coker TP, et al: Treatment of acromioclavicular separations: A retrospective study. *Am J Sports Med 8:* 251–256, 1980
36. Phillips AM, Smart C, Groom AFG: Acromioclavicular dislocation. Conservative or surgical therapy. *Clin Orthop 353:* 10–17, 1998

Downloaded from http://ajs.sagepub.com by MALACHY MCHUGH on November 12, 2008

37. Rockwood CA Jr, Williams GR, Young DC: Disorders of the acromioclavicular joint, in Rockwood CA, Matsen FA (eds): *The Shoulder.* Second edition. Philadelphia, WB Saunders Co, 1998, pp 483–553
38. Sanchez-Sotelo J, Cofield RH, Rowland CM: Shoulder hemiarthroplasty for glenohumeral arthritis associated with severe rotator cuff deficiency. *J Bone Joint Surg 83A:* 1814–1822, 2001
39. Shoji H, Roth C, Chuinard R: Bone block transfer of the coracoacromial ligament in acromioclavicular injury. *Clin Orthop 208:* 272–277, 1986
40. Skjeldal S, Lundblad R, Dullerud R: Coracoid process transfer for acromioclavicular dislocation. *Acta Orthop Scand 59:* 180–182, 1988
41. Stephens HEG: Stuck nail fixation for acute dislocation of the acromioclavicular joint. *J Bone Joint Surg 51B:* 197, 1969
42. Taft TN, Wilson FC, Oglesby JW: Dislocation of the acromioclavicular joint: An end-result study. *J Bone Joint Surg 69A:* 1045–1051, 1987
43. Tsou PM: Percutaneous cannulated screw coracoclavicular fixation for acute acromioclavicular dislocations. *Clin Orthop 243:* 112–121, 1989
44. Vargas L: Repair of complete acromioclavicular dislocation, utilizing the short head of the biceps. *J Bone Joint Surg 24:* 772–773, 1942
45. Walsh WM, Peterson DA, Shelton G, et al: Shoulder strength following acromioclavicular injury. *Am J Sports Med 13:* 153–158, 1985
46. Weaver JK, Dunn HK: Treatment of acromioclavicular injuries, especially complete acromioclavicular separation. *J Bone Joint Surg 54A:* 1187–1194, 1972
47. Weinstein DM, McCann PD, McIlveen SJ, et al: Surgical treatment of complete acromioclavicular dislocations. *Am J Sports Med 23:* 324–331, 1995
48. Wiley AM: Superior humeral dislocation. A complication following decompression and debridement for rotator cuff tears. *Clin Orthop 263:* 135–141, 1991
49. Zaricznyj B: Reconstruction for chronic scapuloclavicular instability. *Am J Sports Med 11:* 17–25, 1983

Downloaded from http://ajs.sagepub.com by MALACHY MCHUGH on November 12, 2008