

## [ Athletic Training ]



# Electromyographic Analysis of the Triceps Surae Muscle Complex During Achilles Tendon Rehabilitation Program Exercises

Michael Mullaney, DPT,<sup>\*,††</sup> Timothy F. Tyler, PT, ATC,<sup>§</sup> Malachy McHugh, PhD,<sup>†</sup> Karl Orishimo, MS,<sup>†</sup> Ian Kremenec, MEng,<sup>†</sup> Jessica Caggiano, DPT,<sup>‡</sup> and Abi Ramsey, DPT<sup>§</sup>

**Background:** Specific guidelines for therapeutic exercises following an Achilles tendon repair are lacking.

**Hypothesis:** A hierarchical progression of triceps surae exercises can be determined on the basis of electromyographic (EMG) activity.

**Study Design:** Randomized laboratory trial.

**Methods:** Bipolar surface electrodes were applied over the medial and lateral heads of the gastrocnemius as well as the soleus on 20 healthy lower extremities (10 participants, 27 ± 5 years old). Muscle activity was recorded during 8 therapeutic exercises commonly used following an Achilles repair. Maximal voluntary isometric contractions (MVICs) were also performed on an isokinetic device. The effect of exercise on EMG activity (% MVIC) was assessed using repeated measures analysis of variance with Bonferroni corrections for planned pairwise comparisons.

**Results:** Seated toe raises (11% MVIC) had the least amount of activity compared with all other exercises ( $P < 0.01$ ), followed by single-leg balance on wobble board (25% MVIC), prone ankle pumps (38% MVIC), supine plantarflexion with red elastic resistance (45% MVIC), normal gait (47% MVIC), lateral step-ups (60% MVIC), single-leg heel raises (112% MVIC), and single-leg jumping (129% MVIC).

**Conclusion:** There is an increasing progression of EMG activity for exercises that target the triceps surae muscle complex during common exercises prescribed in an Achilles tendon rehabilitation program. Seated toe raises offer relatively low EMG activity and can be utilized as an early rehabilitative exercise. In contrast, the single-leg heel raise and single-leg jumping should be utilized only during later-stage rehabilitation.

**Clinical Relevance:** EMG activity in the triceps surae is variable with common rehab exercises.

**Keywords:** exercise prescription; gastrocnemius; soleus

The incidence of Achilles tendon ruptures is as high as 18 per 100 000 per year.<sup>9</sup> Operative management is most common for management of Achilles tendon rupture in relatively young patients.<sup>22</sup> Early weightbearing offers a better early postoperative quality of life.<sup>2,6,7,11,20,21</sup> However, tendon elongation, end-range plantarflexion weakness, and reruptures can occur after surgical repair.<sup>10,12-15,19</sup> Several studies have shown approximately 1 cm of tendon elongation during the first 12 weeks after an Achilles repair without further elongation beyond 12 weeks.<sup>11-13,15</sup> Rettig et al<sup>19</sup> showed that 16.6% of patients 30 years old and younger failed 6 to 10 weeks following repair. The relative weakness of common Achilles repair techniques compared with the potential

forces that the tendon is exposed to during rehabilitation may explain postoperative tendon elongation and subsequent end-range plantarflexion weakness.<sup>1,6,7,11-15</sup>

Percutaneous and open cadaveric Achilles tendon repairs using triple-bundle suturing technique, a Krakow suturing technique, or an augmented Krakow technique fail at approximately 200 N.<sup>3,5,8</sup> Passive Achilles stretch to 10° dorsiflexion results in approximately 120 N<sup>16</sup> of force while walking produces 1500 N.<sup>4</sup> Kangas et al<sup>6</sup> compared an early-motion group versus an immobilization group following an Achilles tendon repair. None of the patients received professional physical therapy but performed postoperative exercises according to a “standard

From the <sup>†</sup>Nicholas Institute of Sports Medicine and Athletic Trauma, New York, New York, <sup>††</sup>Mullaney & Associates Physical Therapy, Matawan, New Jersey, and <sup>§</sup>PRO Sports Therapy of Westchester, Scarsdale, New York

\*Address correspondence to Michael Mullaney, DPT, 127 Main Street, Suite E, Matawan, NJ 07747 (e-mail: mjmullaney@verizon.net).

DOI: 10.1177/1941738111416911

© 2011 The Author(s)

rehabilitation program.<sup>76</sup> Although both groups showed elongation, the early-motion group showed somewhat less elongation as compared with the immobilized group. Patients with less tendon elongation following Achilles repair had better clinical outcomes.<sup>6</sup> Protecting the surgical repair from excessive forces, while facilitating the rehabilitation, is the main goal. The purpose of this study was to develop an electromyogram-based progression of functional exercises for patients after Achilles tendon repair.

## METHODS

### Participants

Ten healthy participants (20 lower extremities; 6 men and 4 women,  $27 \pm 5$  years old) volunteered to participate in triceps surae muscle testing. Participants were excluded if they had a history of lower extremity pathology within the past year or a previous Achilles tendon repair. All participants gave written informed consent. This study was approved by the Institutional Review Board.

### Testing

Following skin prep (shaving, if necessary, skin abrasion, and cleaning with alcohol), participants were instrumented with circular bipolar Ag-AgCl surface electrodes (Noraxon Dual Electrodes, Noraxon USA, Scottsdale, Arizona; diameter, 1 cm; interelectrode distance, 2 cm) bilaterally, on the medial and lateral gastrocnemius and the soleus muscles according to the recommendations of Perotto.<sup>18</sup> A reference electrode was placed on the tibial tuberosity. Muscle activity was recorded at 960 Hz with an 8-channel telemetry system with a bandwidth of 10 to 500 Hz (Noraxon Telemetry, Noraxon USA). Participants performed isometric plantarflexion contractions on a dynamometer (Biodex System 2, Biodex Medical Systems, Inc, Shirley, New York) with the ankle neutral, the knee in full extension, and the trunk at 150°. Three 5-second maximal voluntary isometric contractions (MVICs) were performed while electromyographic (EMG) activity and torque were recorded. Then, three 5-second contractions at 75%, 50%, and 25% MVIC (computer-generated visual feedback) were performed with a 1-minute rest between contractions. Following this, EMG activity was recorded during 8 therapeutic exercises: prone ankle pumps, supine plantarflexion with red elastic resistance (Thera-Band, Hygenic Corporation, Akron, Ohio), seated (nonweightbearing) toe raises, lateral step-ups, single-limb hopping, single-limb heel raises, single-limb balance on wobble board, and normal gait. All EMG data were rectified and smoothed using a root mean square process with a window size of 50 milliseconds.

### Exercise Testing

EMG activity was recorded during the 8 therapeutic exercises: prone ankle pumps, supine plantarflexion with red elastic resistance, seated toe raises, lateral step-ups, single-limb jumps, single-limb heel raises, and single-limb balance on wobble

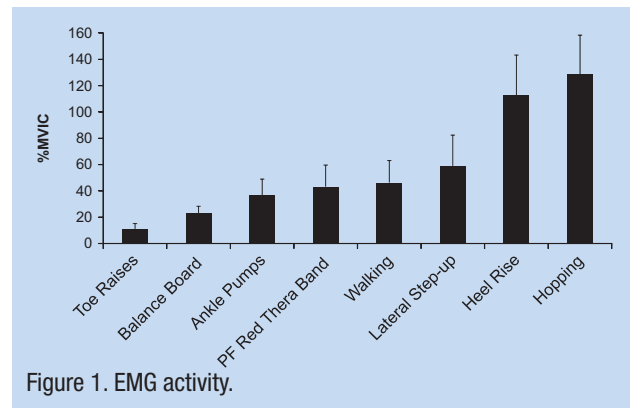


Figure 1. EMG activity.

board. Each exercise was performed for 8 to 10 repetitions and performed to the pace of a metronome to keep pace consistent (1.5 seconds per cycle), except for gait, which was performed at each participant's self-selected pace.

### Statistical Analysis

Based on SPSS version 10.0 statistical software, the linear relationship between the sum of the plantarflexor EMG activity ( $\mu$ V) and percentage MVIC (100%, 75%, 50%, 25%) was plotted for each leg of each participant. The plantarflexor EMG activity during the 8 exercises was expressed as percentage MVIC based on the regression equation. A repeated-measures analysis of variance with Bonferroni corrections for pairwise comparisons was used to examine differences in plantarflexor EMG activity among the exercises.

## RESULTS

EMG activity was lowest for the toe raises exercise (11% MVIC), which was significantly lower than all other exercises ( $P < 0.05$ ) (Figure 1). EMG activity was highest in the hopping (128.9% MVIC) and heel rise (112.6% MVIC). For both exercises, EMG activity was significantly higher than for the other 6 exercises ( $P < 0.05$ ). Balance-board exercise (23.4% MVIC) was significantly lower than red elastic resistance (43.2% MVIC), lateral step-ups (59% MVIC), heel raise, and hopping ( $P < 0.05$ ). Ankle pumps produced 36.7% MVIC and walking produced 43.2% MVIC.

## DISCUSSION

There is a clinical need for a hierarchical exercise progression for Achilles tendon rehabilitation. This EMG analysis of common exercises utilized after Achilles tendon repair provides an objective progression that can be incorporated into accepted rehabilitation guidelines (see Table 1).

### Early-Phase Exercises: 0 to 6 Weeks

Early active tendon mobilization is recommended to decrease scar tissue formation and promote early healing.<sup>17</sup> Thus, toe raises, which had minimal activation (11% MVIC) of the triceps

Table 1. Suggested exercise progression.

Phase	Weeks	% MVIC <sup>a</sup>	Exercise
Early	0-6	0-20	Toe raises
Intermediate	6-9	20-60	Balance board Prone ankle pumps Plantar flexion T-band Walking Lateral step-up
Late	> 9	> 60	Single-heel raise <sup>b</sup> Hopping <sup>b</sup>

<sup>a</sup>Maximal voluntary isometric contraction.

<sup>b</sup>> 12 weeks (> 100% MVIC).

surae, would be an appropriate exercise for the early phase. Flexing the knee can decrease the Achilles tension during dorsiflexion by 40%.<sup>16</sup> Active plantarflexion (prone) produced 38% MVIC, suggesting that it might be more appropriate to delay until the intermediate phase (6-9 weeks).

### Intermediate-Phase Exercises: 6 to 9 Weeks

Unassisted walking activated the triceps surae at 47% MVIC. Balance board (25%), prone ankle pumps (38%), red elastic resistance plantarflexion (45%), and lateral step-ups (60%) were not statistically different from walking. It may be appropriate to introduce these exercises with unassisted walking during the intermediate phase.

### Late-Phase Exercises: > 9 Weeks

Late-phase exercises, such as heel raise and hopping, activated the plantarflexor more than a maximal isometric contraction (heel raise, 110%; hopping, 129%). These exercises should be delayed beyond 12 weeks when the risk on tendon elongation is reduced.<sup>6,7,11-15</sup>

### Limitations

Multiple factors determine the safety of a postoperative rehabilitation program, including surgical technique, suture choices, patient compliance, and degree of muscle activity. This study addressed only 1 of these 4 factors.

## CONCLUSIONS

The degree of muscle activity should be considered when developing a rehabilitation program for soft tissue injuries and/or surgical repairs.

## REFERENCES

- Akizuki KH, Gartman EJ, Nisonson B, Ben-Avi S, McHugh MP. The relative stress on the Achilles tendon during ambulation in an ankle immobiliser: implications for rehabilitation after Achilles tendon repair. *Br J Sports Med.* 2001;35(5):329-333.
- Costa ML, Shepstone L, Darrah C, Marshall T, Donell ST. Immediate full-weight bearing mobilization for repaired Achilles tendon ruptures: a pilot study. *Injury.* 2003;34:874-876.
- Cretnik A, Zlajpah L, Smrkoli V, Kosanovic M. The strength of percutaneous methods of repair of the Achilles tendon: a biomechanical study. *Med Sci Sports Exerc.* 2000;32:16-20.
- Finni T, Komi PV, Lukkariniemi J. Achilles tendon loading during walking: application of a novel optic fiber technique. *Eur J Appl Physiol Occup Physiol.* 1998;77(3):289-291.
- Jaakkola JI, Hutton WC, Beskin JL, Lee GP. Achilles tendon rupture repair: biomechanical comparison of the triple bundle technique versus the Krakow locking loop technique. *Foot Ankle Int.* 2000;21:14-17.
- Kangas J, Pajala A, Ohtonen P, Leppilahti J. Achilles tendon elongation after a rupture repair. *Am J Sports Med.* 2007;35(1):59-64.
- Kangas J, Pajala A, Siira P, Hamalainen M, Leppilahti J. Early functional treatment vs early immobilization in tension of the musculotendinous unit after Achilles rupture repair: a prospective, randomized clinical study. *J Trauma.* 2003;54(6):1171-1181.
- Lee S, Sileo M, Kremencic I, et al. Cyclic loading of 3 Achilles tendon repairs simulating early postoperative forces. *Am J Sports Med.* 2009;37(4):786-790.
- Leppilahti J, Puranen J, Orava S. Incidence of Achilles tendon rupture. *Acta Orthop Scand.* 1996;67(3):277-279.
- Leppilahti J, Siira P, Vanharanta H, Orava S. Isokinetic evaluation of calf muscle performance after Achilles rupture repair. *Int J Sports Med.* 1996;17(8):619-623.
- Maffulli N, Tallon C, Wong J, Lim KP, Bleakney R. Early weightbearing and ankle mobilization after open repair of acute midsubstance tears of the Achilles tendon. *Am J Sports Med.* 2003;31(5):692-700.
- Mortensen NH, Saether J, Steinke MS, Staehr H, Mikkelsen SS. Separation of tendon ends after Achilles tendon repair: a prospective, randomized, multicenter study. *Orthopedics.* 1992;15(8):899-903.
- Mortensen NH, Skov O, Jensen PE. Early motion of the ankle after operative treatment of a rupture of the Achilles tendon: a prospective, randomized clinical and radiographic study. *J Bone Joint Surg Am.* 1999;81(7):983-990.
- Mullaney MJ, McHugh MP, Tyler TF, Nicholas SJ, Lee SJ. Weakness in end-range plantar flexion after Achilles tendon repair. *Am J Sports Med.* 2006;34(7):1120-1125.
- Nystrom B, Holmlund D. Separation of tendon ends after suture of Achilles tendon. *Acta Orthop Scand.* 1983;54(4):620-621.
- Orishimo KF, Burstein G, Mullaney MJ, et al. Effect of knee flexion angle on Achilles tendon force and ankle joint plantarflexion moment during passive dorsiflexion. *J Foot Ankle Surg.* 2008;47(1):34-39.
- Palmes D, Spiegel HU, Schneider TO, et al. Achilles tendon healing: long-term biomechanical effects of postoperative mobilization and immobilization in a new mouse model. *J Orthop Res.* 2002;20(5):939-46.
- Perotto A. *Anatomical Guide for the Electromyographer.* 3rd ed. Springfield, IL: Charles C Thomas; 1994.

19. Rettig AC, Liotta FJ, Klootwyk TE, Porter DA, Mieling P. Potential risk of rerupture in primary Achilles tendon repair in athletes younger than 30 years of age. *Am J Sports Med.* 2005;33(1):119-123.
20. Speck M, Klaue K. Early full weightbearing and functional treatment after surgical repair of acute Achilles tendon rupture. *Am J Sports Med.* 1998;26(6):789-793.
21. Suchak A, Bostick G, Beaupré LA, Durand D, Jomha NM. The Influence of early weight-bearing compared with non-weight-bearing after surgical repair of the Achilles tendon. *J Bone Joint Surg Am.* 2008;90:1876-1883.
22. Wong J, Barrass V, Maffulli N. Quantitative review of operative and nonoperative management of Achilles tendon ruptures. *Am J Sports Med.* 2002;30(4):565-575.

---

For reprints and permission queries, please visit SAGE's Web site at <http://www.sagepub.com/journalsPermissions.nav>.